



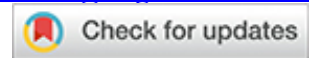
Preliminary study on intraocular abnormalities found in senior dogs by ultrasonography in a veterinary hospital in Guayaquil, Ecuador

López-Colom Paola ¹, Maridueña-Zavala María Isabel ^{2*}

¹Universidad Agraria del Ecuador UAE, Facultad de Medicina Veterinaria y Zootecnia, Campus Dr. Jacobo Bucaram Ortiz-Guayaquil. Av. 25 de Julio y Av. Pío Jaramillo Alvarado Apartado 090107 /Guayaquil /Ecuador; paola.lopecol@gmail.com.

²Universidad Agraria del Ecuador UAE, Facultad de Medicina Veterinaria y Zootecnia, Campus Dr. Jacobo Bucaram Ortiz-Guayaquil. Av. 25 de Julio y Av. Pío Jaramillo Alvarado Apartado 090107 /Guayaquil /Ecuador.

* Correspondence: mmariduenaa@uagraria.edu.ec



ABSTRACT

Research on ophthalmology in veterinary medicine in Ecuador is scarce, and ocular health in older dogs should be studied. This study aimed to determine the incidence of ophthalmic abnormalities in senior dogs attending a hospital at Guayaquil and relate them to the type of lesion, breed, sex, age, and type of dog head shape. One hundred healthy senior dogs (> six years old) who underwent consultation during the study were subjected to bilateral eye ultrasonography (USG 10-MHz transducer) and examined for ocular alterations. Breed, sex, age, and head shape were also recorded. Thirty-eight animals presented with ocular abnormalities: presumed cataracts (19%), crystalline luxation (6%), presumed senile retinal degeneration (6%), retinal detachment (4%), nuclear sclerosis (4%), masses and vitreous degeneration (3%), presumed glaucoma (2%), and cysts in the anterior and posterior chambers (1%), mainly as bilateral lesions (24%). Cataracts were present in a more significant proportion in dolichocephalic dogs (8/18) than in brachycephalic (3/22) and mesocephalic dogs (8/60) ($p=0.01$). In addition, older animals were more affected, both unilaterally and bilaterally, and in both locations (lens or retina) ($p<0.05$), whereas crystalline luxation and senile retinal degeneration were significantly associated with age ($p<0.05$), whereas trends were observed for cataracts ($p=0.065$). Although ultrasound alone does not allow a definitive diagnosis, these preliminary results provide insights into the ocular abnormalities in apparently healthy senior dogs from Guayaquil (Ecuador). Unsuspected intraocular lesions might be relatively high in these patients; however, more extensive studies with complete ocular examination are recommended to confirm these results.

Keywords: Aging dog; Cataracts; Retinal lesion; Ultrasonography

INTRODUCTION

Senior dogs should follow a health plan to prevent, diagnose, and treat the disease according to their age and specific physiological demands. Older dogs are required to undergo regular checkups¹ and ocular examination is recommended to include². However, ophthalmological visits start at later ages^{3,4} since owners may not recognize early clinical signs or assume alterations as expected for these ages⁵, and unsuspected diseases affecting the internal eye of senior dogs might be omitted in routine⁶, posing a risk of deterioration of ocular health.

Research on ophthalmology in veterinary medicine in Ecuador is still incipient⁷. Animals are seldom subjected to ocular examination; wherever possible, it is costly and time-consuming^{8,9}. Moreover, the reagents required are sometimes unavailable, and the income of owners attending consultations usually does not allow further examination. Ultrasound is used to visualize most structures within the animal's body. The selection of this method for the research is due to its practicality. It allows the internal structures of the eye to be quickly visualized; in addition, this technique is not invasive and minimizes discomfort for the animal and irritation in the ocular area, which can generally interfere with the sample collection¹⁰. The use of noninvasive, simple, and fast techniques allows to optimize the diagnosis in an animal, in addition, it has been found that other alterations can lead to eye problems such as has been found that the natural degeneration of some structures, such as the teeth, is a source of possible alterations in the structures that surround the eye², it is common for teeth not to be checked regularly. Other diseases, such as cataracts, are commonly caused by natural degeneration or interaction with endocrine-type diseases¹¹.

Hence, this study aimed to determine the presentation and type of ocular abnormalities in apparently healthy senior dogs using ultrasonography as a primary diagnostic imaging and noninvasive method¹² that allows the top to visualize what clinical eye is incomplete at first glance. In addition, considering a scenario where resources are scarce, basic information regarding the patient (sex, age, breed, head shape) was registered to provide veterinarians with insights into superficial animal characteristics related to ophthalmologic alterations.

MATERIALS AND METHODS

Sample population

Animal manipulation and care were performed following the standards recommended by EU Directive 2010/63/EU for animal experiments¹³. The pet owners agreed to participate, and consent was obtained from the animals involved in this study.

Dogs attending the veterinary hospital for biannual routine examinations, identified as senior patients (> six years old) with no currently known health issues and without previous ophthalmic examinations or ocular problems diagnosed, were selected. A total of 100 patients (200 eyes) were evaluated. Data on sex, age, breed, and type of dog head were recorded. The breeds attending the hospital and represented by Boxer, Boston Terrier, French Bulldog, Chihuahua, Maltese, Pekingese, and Shih Tzu were considered brachycephalic, crossbreeds and Akita, Beagle, Cocker Spaniel, Dalmatian, Golden Retriever, Husky, Jack Russell Terrier, Labrador Retriever, Pitbull, Pomeranian, Schnauzer, Silky Terrier, and Yorkshire Terrier were considered mesocephalic, and Dachshund and Poodle were considered dolichocephalic, based on previous classifications^{14,15}.

Ocular ultrasound

USG was performed following procedure¹⁶ in which the animals were not sedated. The small animals underwent a bilateral ophthalmological examination in sternal recumbency by trans-corneal ocular ultrasonography utilizing a 10 MHz linear transducer (Sonosite 1800, Fujifilm) in the axial plane to confirm the presence, type, and location of intraocular alterations. The probe was placed directly over the cornea or sclera, and the eyelids were manually opened. Ocular abnormalities recorded included crystalline luxation, retinal detachment, abnormal vitreous, presumed cataracts, cysts in the anterior chamber, glaucoma, nuclear sclerosis, and senile retinal degeneration.

Statistical analysis

Statistical analyses were performed using R v4.2.2¹⁷. Data were summarized as percentages, means, and standard deviations. To determine possible relationships between the presentation of ocular alterations and intrinsic animal characteristics, a chi-square test (to evaluate breed, sex, and type of head shape) and ANOVA (to evaluate age) were applied. Age was also determined as a predictor of ocular abnormalities using logistic regression and receiver operating characteristic (ROC) curve analysis to determine the area under the curve (AUC). The optimal cut-off value was estimated for ROC curves above 0.50 with a 95% confidence interval, and the sensitivity (SE) and specificity (SP) were calculated.

RESULTS AND DISCUSSION

This study evaluated ocular abnormalities in Senior dogs at the Veterinary clinic in Guayaquil over two months, which was the peak time for patients presenting with these symptoms; during this time, the number of samples was 100 dogs. The increase in consultations in this specialty area was attributed to the clinic's advanced facilities for conducting thorough eye evaluations. Of the 100 dogs evaluated, half were male, half were female (53% and 47%, respectively), and the average age was 8.72 ± 2.40 years old. Poodles (16%), Yorkshire terriers (14%), and crossbreeds (11%) were the most common breeds attended, followed by Schnauzers and Shih Tzu (both at 8%). The remaining 43 dogs were comprised of 18 breeds. Most head shapes corresponded to mesocephalic breeds (60%), whereas 22% were brachycephalic, and 18% were dolichocephalic (Table 1).

Breed	Proportion (%)
Poodle	16
Yorkshire terrier	14
Crossbred	11
Schnauzer	8
Shih Tzu	8
Beagle	5
Chihuahua	5
Cocker Spaniel	5
Labrador Retriever	5
Golden Retriever	4
Boxer	3
Maltese	3
Dalmatian	2
Dachshund	2
Akita	1
Boston Terrier	1
French Bulldog	1
Husky	1
Jack Russell Terrier	1
Pekingese	1
Pitbull	1
Pomeranian	1
Silky Terrier	1

Table 1. Breeds of senior dog patients were included in the study (N = 100).

Concretely, thirty-eight dogs showed, in at least one eye, ocular abnormalities, reported as presumed cataracts (19%), crystalline luxation (6%), presumed senile retinal degeneration (6%), retinal detachment (4%), presumed nuclear sclerosis (4%), masses and abnormal vitreous humor (3%), presumed glaucoma (2%), and cysts in the anterior (1%) and posterior (1%) chambers. Most animals had bilateral alterations (24%), mainly consisting of bilateral cataracts (n=9), senile retinal degeneration (n=5), crystalline luxation (n=3), nuclear sclerosis (n=2), and retinal detachment (n=1). Two animals presented with two simultaneous lesions in one eye (left eye), consisting of retinal detachment and glaucoma, a cataract, and a cyst in the anterior chamber. Figure 1 presents a comparison between a Retinal detachment and a normal eye.

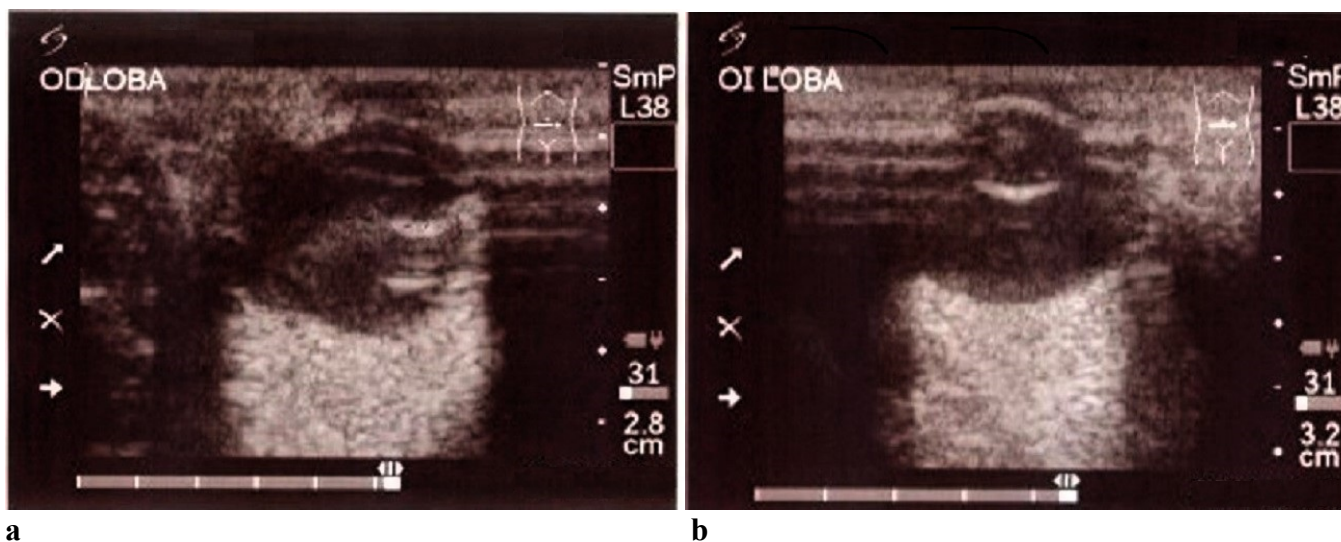


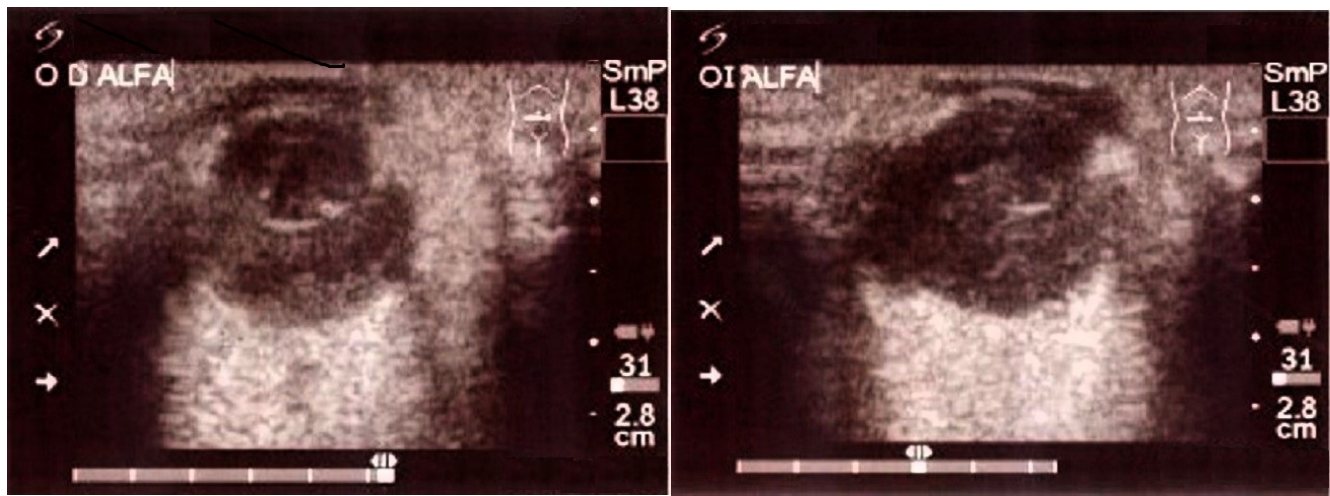
Figure 1. (a) Retinal detachment, female 84 months old; (b) Cataracts in the left eye, female 84 months old

Of the 100 dogs evaluated, 38% had some internal eye alteration, a proportion found to be inferior to a previous study with apparently healthy senior and geriatric dogs (66%)⁵ and superior to studies with dogs of any age, with incidences of approximately 15%^{2,4}, focused on brachycephalic breeds. In our study, either breed or head shape was unrelated to presenting ocular alterations, either unilateral or bilateral ($p > 0.15$) (data not shown), although some brachycephalic breeds suffered tear desiccation, lagophthalmos, and exophthalmia^{2,4}, generally associated with ocular surface diseases that we did not observe. To confirm these differences, however, the method of diagnosis might have influenced the different results and hindered direct comparison since ultrasonography is a complementary technique to ocular examination and should be accompanied by techniques such as tear evaluation, which was not implemented in the present study. The use of exploratory techniques such as slit lamp biomicroscopy and ophthalmoscopy has impacted the advancement of both human and veterinary ophthalmology, enhancing our diagnostic capabilities.¹⁸ In any case, comparisons could also be limited because some animals enrolled in the study were unlikely to be purebred, and there was a relative variety of breeds, most of them underrepresented, and some lesions appeared at different ages depending on the breed¹⁹.

Nevertheless, in the case of head shape, a remarkably more significant proportion of dolichocephalic dogs (> 3-fold) presented cataracts than brachycephalic and mesocephalic dogs (8/18, 3/22, and 8/60, respectively; $p = 0.010$). Cataracts are observed in older animals^{8,20} (figure 2), but age was similar among the three head shapes (dolichocephalic 9.1 ± 2.62 years old, brachycephalic 9.0 ± 2.46 years old, and mesocephalic 8.5 years old, $p = 0.536$). Another explanation could be that the most significant proportion of Poodles is dolichocephalic (8/18), a breed with a hereditary predisposition to cataracts²⁰.

A comparison of the average age between healthy and diagnosed dogs is shown in Table 2. Older animals were more frequently diagnosed with intraocular abnormalities, either unilateral or bilateral ($p < 0.001$), and in both locations (lens or retina, $p < 0.01$). When evaluated by type, crystalline luxation ($p = 0.015$) and senile retinal degeneration ($p = 0.003$) were significantly associated with older age. Accordingly, ROC curve AUCs; ≥ 0.58 when evaluating the presentation of any type, lesion (cut-off 10.5 years; SE 42.1%; SP 87.1%), retina

(cut-off 10.5 years; SE, 62.5%; SP, 88.2%), lens (cut-off 9.5 years; SE, 48.3%; SP, 73.2%), retina (cut-off 10.5 years; SE 66.7%; SP 80.2%), crystalline luxation (cut-off 7.5 years old; SE, 100%; SP, 42.6%), and senile retinal degeneration (cut-off 10.5 years old; SE 83.0%; SP 79.8%).



a **b**
Figure 2. (a) Cataracts in the right eye, male 132 months old; (b) Cataracts in the left eye, male 132 months old.

Pathology	Healthy	Confirmed	RSE	pvalue
Any lesion	8.08 (62)	9.76 (38)	2.262	0.001
Bilateral lesion	8.12 (76)	10.63 (24)	2.151	0.001
Lens lesion	8.32 (71)	9.69 (29)	2.325	0.009
Cataracts	8.51 (81)	9.63 (19)	2.366	0.065
Crystalline luxation	8.57 (94)	11.00 (6)	2.336	0.015
Nuclear sclerosis	8.75 (96)	8.00 (4)	2.403	0.542
Retina lesion	8.52 (91)	10.78 (9)	2.317	0.006
Senile degeneration	8.54 (94)	11.50 (6)	2.301	0.003
Retinal detachment	8.66 (96)	10.25 (4)	2.387	0.194

Table 2. Differences in average age in years (and number of cases) between healthy dogs and dogs diagnosed with presumed ocular lesions. RSE: Residual standard error.

As expected, age was related to the presentation of any ocular abnormalities (in the lens and retina); specifically, patients aged 10.5 and above were observed to be at greater risk. Moreover, bilateral alterations were observed in older animals. Although cataracts were the most common lesion diagnosed (19%), they tended to increase with age ($p < 0.10$). In this sense, cataracts rise above 10 years old⁹, and animals in our study were, on average, younger (8.72 ± 2.40 years old), which could have prevented us from observing further differences. In addition, other underlying etiologies, such as diabetes, can lead to cataracts⁸, which were not considered and cannot be ruled out. Concurrent ocular diseases may also pose a risk of cataracts, such as vitreous degeneration^{8,11,19}, but in our study, only one eye (out of 200 eyes) showed simultaneous cataracts and a cyst in the posterior chamber. Similarly, nuclear sclerosis was unaffected by age. However, all presumed cases ($n = 4$) were detected in dogs above seven years old, which is consistent with the findings of Tobias et al.²¹. However, it is important to highlight that ultrasonography alone does not allow a definitive diagnosis of cataracts or nuclear sclerosis, since increments of echogenicity in the nucleus of the lens can be confused with both lesions (specifically senile cataracts)²².

This study aimed to demonstrate that ultrasound can be effectively implemented as an additional diagnostic method for patients with ocular pathologies, regardless of the etiology. Ultrasound is particularly valuable for detecting lesions obscured by corneal or lens opacities, allowing for observing internal structures relatively cheaply. When this technique is used alongside other diagnostic methods, ultrasound can help achieve a definitive diagnosis. Similar studies, such as the evaluation of 15 senior dogs in Mexico City, have demonstrated the utility of ultrasound in diagnosing conditions like neoplasias, cataracts, and degenerative diseases.²³

Pet care and health are becoming increasingly important in veterinary practice in Ecuador. However, our media has published no studies on specific disciplines, such as ophthalmology⁷, and even fewer studies on senior animals. This study is the first in the country to provide evidence of unsuspected intraocular lesions in senior dogs. The study was conducted in a specific population within a sector of Guayaquil characterized by a recurring number of patients. The demographic characteristics of this population showed considerable variability; a similar study was carried out in Cuba,²⁴ where pet owners of different genders and socioeconomic levels were present; usually, the primary reason for attending consultations is the perception of pets as family members. Therefore, this cultural perspective significantly influences the frequency and nature of veterinary visits and is aimed at promoting routine ocular examinations by owners and veterinarians, especially in older patients.

CONCLUSIONS

In summary, ophthalmic abnormalities are common in apparently healthy senior dogs in the northern sector of Guayaquil; therefore, professionals play a central role in improving health and promoting care and owner awareness in aging dogs among owners. This study exclusively utilized ultrasonography to demonstrate its effectiveness as a complementary diagnostic method, particularly for observing internal eye structures when ocular opacities appear and that are unrelated to other pathologies.

This study included a small group of dogs of various breeds that attended checkups within the two months. The results demonstrated the ocular diagnosis of a small sample of a specific city zone with a heterogeneous dog population. It is essential to consider that future studies should increase the number of locations sampled from different parts of the city to cover a larger population. Additionally, the number of patients of different ages and the implementation of various diagnostic methods should be considered to enhance the precision of the diagnoses.

Contributions: Conceptualization, methodology, validation, and formal data analysis, as well as data curation, were developed by María Isabel Maridueña Zavala, and manuscripts preparation, writing and review were performed by Paola López Colon.

Funding: This research received no external funding.

Institutional Review Board Statement: The study was conducted according to the standards guidelines of the EU Directive 2010/63/EU of the European Parliament of the Council on protecting animals used for scientific purposes.

Informed Consent Statement: Not applicable.

Conflicts of Interest: The authors declare no conflict of interest.

REFERENCES

1. Dhaliwal R, Boynton E, Carrera-Justiz S, Cruise N, Gardner M, Huntingford J, et al. 2023 AAHA Senior Care Guidelines for Dogs and Cats. *J Am Anim Hosp Assoc*. 2023 Jan 1;59(1):1–21.
2. Sebbag L, Silva APSM, Santos ÁPB, Raposo ACS, Oriá AP. An eye on the Shih Tzu dog: Ophthalmic examination findings and ocular surface diagnostics. *Vet Ophthalmol*. 2023 Apr 1;26(S1):59–71.
3. Kim JY, Kim KH, Williams DL, Lee WC, Jeong SW. Epidemiological and clinical features of canine ophthalmic diseases in seoul from 2009 to 2013. *Journal of Veterinary Clinics*. 2015 Jul 21;32(3):235–8.
4. Palmer S, Espinheira Gomes F, McArt J. Ophthalmic disorders in a referral population of seven breeds of brachycephalic dogs: 970 cases (2008–2017). *JAVMA*. 2021;259(11):1–7.
5. Willems A, Paepe D, Marynissen S, Smets P, Van de Maele I, Picavet P, et al. Results of Screening of Apparently Healthy Senior and Geriatric Dogs. *J Vet Intern Med*. 2017 Jan 1;31(1):81–92.
6. Labruyere JJ, Hartley C, Holloway A. Contrast-enhanced ultrasonography in the differentiation of retinal detachment and vitreous membrane in dogs and cats. *Journal of Small Animal Practice [Internet]*. 2011 Oct 1;52(10):522–30. Available from: <https://doi.org/10.1111/j.1748-5827.2011.01099.x>
7. Giannetto C, Macrì F, Falcone A, Giudice E, Crupi R, Cicero L, et al. Evaluation of tear production as measured by schirmer test i in dogs after acepromazine and acepromazine–methadone premedication. *Animals*. 2021 Nov 1;11(11).
8. Fischer MC, Meyer-Lindenberg A. Progression and complications of canine cataracts for different stages of development and aetiologies. *Journal of Small Animal Practice [Internet]*. 2018 Oct 1;59(10):616–24. Available from: <https://doi.org/10.1111/jsap.12910>
9. Park SA, Yi NY, Jeong MB, Kim WT, Kim SE, Chae JM, et al. Clinical manifestations of cataracts in small breed dogs. *Vet Ophthalmol*. 2009 Jul;12(4):205–10.
10. Aironi VD, Gandage SG. Pictorial essay: B-scan ultrasonography in ocular abnormalities. Vol. 19, *Indian J Radiol Imaging*. 2009.
11. Park YW, Kim JY, Jeong MB, Kim SH, Yoon J, Seo K. A Retrospective study on the association between vitreous degeneration and cataract in dogs. *Vet Ophthalmol [Internet]*. 2015 Jul 1;18(4):304–8. Available from: <https://doi.org/10.1111/vop.12230>
12. Britti D, Di Pietro S, Russo M, Pugliese A, De Majo M. Doppler Evaluation of the Ophthalmic Vasculature in the Beagle: Normal Values. *Vet Res Commun*. 2003;1:373–6.
13. European parliament. Directive 2010/63/EU of the European Parliament of the council on the protection of animals used for scientific purposes. *Official Journal of the European Union*. 2010 Sep 22;1–47.
14. Littles ME, Rao S, Banoon Kristin. Analysis of the anatomic relationship of the infraorbital canal with the roots of the maxillary fourth premolar tooth in the three different skull types: Mesocephalic, brachycephalic, and dolichocephalic, using cone beam computed tomography. *Front Vet Sci*. 2022;
15. Schoenebeck JJ, Ostrander EA. The genetics of canine skull shape variation. *Genetics*. 2013;193(2):317–25.
16. Sánchez Bustamante LM, Rivas Guerrero JF, Vargas Pinto PA. Exploración ecográfica ocular básica en perros (modo B tiempo real). *Rev Med Vet (Bogota)*. 2016 Nov 30;(33):113–24.
17. Venables WN, Smith DM. An Introduction to R Notes on R: A Programming Environment for Data Analysis and Graphics. 2024. p. 1–103.
18. Bayón Del Río A, Palao Jiménez C, Micó Valls C, Vecino Cordero E. Veterinary ophthalmology: From cataract surgery to OCT. *Arch Soc Esp Oftalmol*. 2010;85(12):387–9.
19. Krishnan H, Diehl K, Stefanovski D, Aguirre GD. Vitreous degeneration and associated ocular abnormalities in the dog. *Vet Ophthalmol [Internet]*. 2020 Mar 1;23(2):219–24. Available from: <https://doi.org/10.1111/vop.12707>
20. Park SA, Yi NY, Jeong MB, Kim WT, Kim SE, Chae JM, et al. Clinical manifestations of cataracts in small breed dogs. *Vet Ophthalmol*. 2009 Jul;12(4):205–10.

21. Tobias G, Tobias T, Abood SK. Estimating age in dogs and cats Using Ocular Lens Examination. Compendium on Continuing Education for the Practising Veterinarian -North American Edition [Internet]. 2000;22(12). Available from: <https://www.researchgate.net/publication/298604604>
22. Pizzirani SPDSK. Atlas of Small Animal Ultrasonography. 2015.
23. Romero Ramírez M, Díaz González VS, Quiroz Mercado J, Reyes Alva H. Principales hallazgos ecográficos observados en enfermedades oculares en 15 perros remitidos al HVPE-FMVZ-UAEMex. Mexico; 2015 Jun.
24. Hugues B, Torres M. Datos demográficos de animales de compañía atendidos en consulta de oftalmología y de las personas a su cargo. Vol. 25, Rev Inv Vet Perú. 2014.

Received: December 14, 2023/ **Accepted:** February 25, 2024 / **Published:** June 15, 2024

Citation: López-Colom Paola; Maridueña-Zavala María Isabel. Preliminary study on intraocular abnormalities found in senior dogs by ultrasonography in a Veterinary Hospital in Guayaquil, Ecuador. Bionatura journal 2024; 1 (2) 16. <http://dx.doi.org/10.70099/BJ/2024.01.02.16>

Additional information Correspondence should be addressed to mmariduenaa@uagraria.edu.ec

ISSN. 3020-7886

Peer review information. Bionatura thanks anonymous reviewer(s) for their contribution to the peer review of this work using <https://reviewerlocator.webofscience.com/>

All articles published by Bionatura Journal are made freely and permanently accessible online immediately upon publication, without subscription charges or registration barriers.

Publisher's Note: Bionatura Journal stays neutral concerning jurisdictional claims in published maps and institutional affiliations.

Copyright: © 2024 by the authors. They were submitted for possible open-access publication under the terms and conditions of the Creative Commons Attribution (CC BY) license (<https://creativecommons.org/licenses/by/4.0/>).